



Lingualized Occlusion: An Emerging Treatment Paradigm For Complete Denture Therapy: A Review Article

Dr. Rupali Kamath¹, Dr. Sarandha D.L², Dr. Smitha Thomas³,
Dr. Bhavika Sachdeva⁴

Department of Computer Science, Faculty of IT, WISE University, Amman, Jordan

Received 09 March, 2015; Accepted 26 March, 2015 © The author(s) 2015. Published with open access at www.questjournals.org

ABSTRACT : As we all know that in the success of a complete denture restoration occlusion plays an very important role in providing the retention, stability and support of the denture. Various occlusal schemes have been proposed for the complete denture therapy but none have been proved or accepted universally. Lingualized occlusions provides a useful combination of various occlusal schemes and have many advantages over other occlusal schemes. This article gives review about the development of lingualized occlusion and its emergence as an efficient occlusion over various other schemes and its advantages and indications.

Keywords: - complete denture, occlusion, lingualized occlusion.

I. INTRODUCTION

Occlusion is defined as the “static relationship between the incisive and masticatory surfaces of maxillary and mandibular teeth or analogues of teeth” (GPT 1994). Occlusal concepts and their resulting functions are of concern to the dentist so that loss of remaining tissues of the mouth, which may be attributed to the malocclusion that can be minimized [1]. The search for an ideal artificial tooth arrangement that maximized denture stability , comfort, aesthetics and function have occupied the dental literature for many years [2]. Of the many schemes that have been presented to the dental profession , lingualized occlusion has been emerged as one of the most popular scheme. It is a valuable concept because it blends many of the anatomy and the mechanical schools of thought. It has the advantages of both anatomic and non anatomic occlusion.

Lingualized occlusion can be defined as, the form of denture occlusion that where the maxillary lingual cusps articulate with the mandibular occlusal surfaces(Fig1) in centric 7 working and non-working mandibular positions . Lingualized occlusion should not be confused with placement of the mandibular teeth lingual to the ridge. (Fig 2)

Lingualized occlusion is an attempt to maintain the esthetics with advantages of the anatomic form while maintaining the mechanical freedom of non anatomic form. Lingualized occlusion utilizes anatomic teeth for the maxillary denture and modified non anatomic or semi anatomic teeth for mandibular denture. The umbrella term lingualized occlusion can be used in many ways encompassing linear, organic, balanced, nonbalanced, functional rational and functional occlusion[3].

HISTORY

Gysi was first to design and patent “Cross-Bite Posterior Teeth” in 1927 . Each maxillary tooth featured a single, linear cusp that fit into shallow mandibular depression. So the Concept of lingualized occlusion was introduced by Alfred Gysi in 1927 (Fig 3)

S.H. Payne (1941): In 1941, when Payne introduced a more clear form of lingualized occlusion. Payne credited Farmer with development of this technique, and provided a brief description of the required laboratory procedures. According to Payne's article, a mortar-and-pestle arrangement was created via judicious recontouring of 30-degree teeth

Pound: Finally introduced the term 'lingualized occlusion.[3,4]

II. INDICATIONS

Lingualised occlusion can be used in most denture combinations.

- a) It is particularly helpful when the patient places high priority on esthetics but non-anatomic occlusal scheme is indicated because oral conditions such as severe alveolar resorption, a Class II jaw relationship, or displaceable supporting tissue. If the non-anatomic occlusal scheme is used, esthetics in the premolar region are compromised. With Lingualised occlusion, the esthetic result is greatly improved while still maintaining the advantages of a non-anatomic system.
- b) Lingualised occlusion also can be used effectively when a complete denture opposes a removable partial denture as in case of combination syndrome and bilateral balanced occlusion is desirable.[5]
- c) Patients having parafunctional habits, so that reduced amount of horizontal forces are transmitted to supporting tissues.
- d) In patients with implant supported overdenture.

III. PRINCIPLES OF LINGUALIZED OCCLUSION

According to Becker Principles of lingualized occlusions are:[6,7]

- a) Anatomic posterior (30-33 degree) teeth are used for maxillary denture. Tooth forms with prominent lingual cusps are useful.
- b) Non anatomic or semi anatomic teeth are used for mandibular denture . Either a shallow or a flat cusp form is used. Narrow occlusal form is preferred where resorption of residual ridge has occurred.
- c) Modification of mandibular posterior teeth is accomplished by selective grinding which is always necessary regardless of the material used.
- d) Maxillary lingual cusp contact mandibular teeth in centric occlusion
- e) Balancing and working contacts should occur only on the maxillary lingual cusps.
- f) Protusive contacts only between upper lingual cusps and lower teeth.

IV. CRITERIA FOR ARRANGING TEETH IN LINGUALIZED OCCLUSION

In lingualized occlusion concept, only the lingual cusps of the posterior teeth of the upper denture make contact in centric relation in the central fossae of the lower posteriors. The buccal cusps are out of contact. There is therefore only one "centric stop" between upper and lower antagonistic pair of posterior teeth. This is achieved by arranging the teeth in such a way that on both the working (active) side and the balancing (passive) side there are simultaneous bilateral balancing contacts.

In order to guarantee a balanced occlusion, a compensation curve is arranged during the set-up of the mandibular posterior teeth. No posterior teeth are placed in the ascending part of the mandible in order to prevent protrusive dislocation of the lower denture.

During protrusive balance , anterior teeth should be out of contact. If anterior interference occurs, either move or grind the opposing lower anterior teeth slightly or increase the distal incline on the lower molars by increasing the compensating curve.

The fossae of the lower posterior teeth must be broadened, mainly by means of selective grinding to allow for the free movement of the upper lingual cusp over the lower central fossae.

This way the working and balancing cusp contacts are simplified, since only the upper lingual cusp contacts the lower occlusal surfaces.

V. ADVANTAGES OF LINGUALIZED OCCLUSION[3,8,9]

- Cross arch balance thus resulted in improved denture stability and enhanced patient comfort.
- Reduced lateral forces because only the lingual cusp of the maxillary teeth provides the sole contact with the mandibular posterior teeth
- Vertical forces are centered upon the mandibular residual ridges.
- Simplified tooth arrangements , simplified occlusal adjustments , reduced lateral forces, good esthetics and efficient bolus penetration
- Provides a mortar and pestle type of occlusion with cusp teeth to provide a smaller occlusal contact for more efficiency and control of resultant forces.

- The upper posteriors can be positioned more buccally on the ridge, because only the lingual cusps are active and should be situated at the top of the maxillary ridge. In many cases, this eliminates the need for crossbite arrangement and improves the functional and the aesthetic aspects of the dentures.
- The facial muscles and the cheeks are well supported by the more buccally placed maxillary molars, which increases the aesthetics value even more.

VI. FIGURES

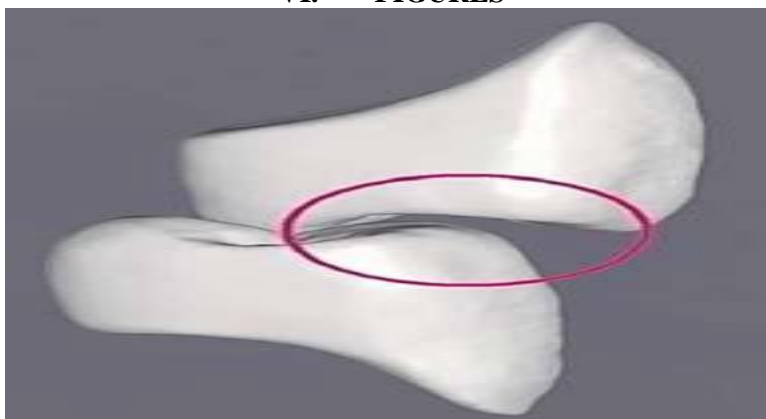


Fig 1- Maxillary lingual cusp occludes with the lower central fossa

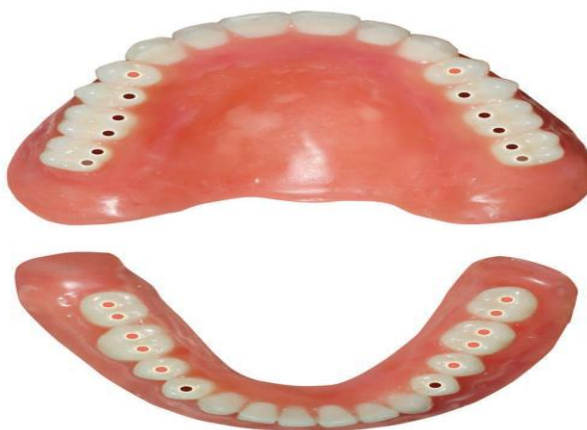

Fig 2- Centric occlusal contacts in lingualized set up

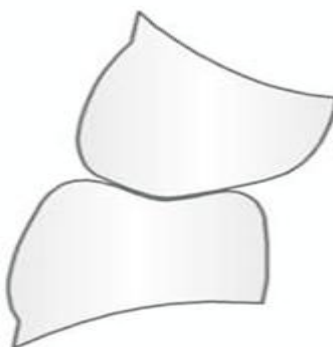


Fig 3- Gysi's cross bite teeth

VII. CONCLUSION

Lingualized occlusion is not a temporary trend, but a clinical necessity. This concept of occlusion enables a reduction of the forces transmitted onto the denture bearing areas, a 50% higher masticatory efficiency, since teeth with cusps are used, and different approaches to solving specific clinical problems. In

general it can be said that there are no contra-indications for the lingualized occlusion concept. This concept is indicated for doctors and patients who place high aesthetic requirements on their dentures and when the goal is to minimize the horizontal forces during mastication and arafunctional movements in cases of severe alveolar bone resorption, flabby and knife edge ridges, abnormal jaw relation like cross arch and large interalveolar space.

Lingualized occlusion is a simple occlusal scheme to practice. It can be modified to fit many different situations like when anatomic or non-anatomic teeth are to be used with a balanced or non-balanced occlusion. It can also be used in complete or partial denture, overdenture, immediate dentures or transitional dentures. It, indeed, is an occlusion for all reason.

REFERENCES

- [1]. Savitha K. C., Srinivas L. Shantaraj, Occlusal Schemes for Complete Dentures - A Review Article, BHAVNAGAR UNIVERSITY'S JOURNAL OF DENTISTRY, 3 (1) 2013,67-72.
- [2]. Lang BR. Complete denture occlusion. Dent Clin North Am 1996; 40:85-91.
- [3]. Kumar M, Thomas V et al, LINGUALIZED OCCLUSION- A SURROGATE TO SUCCESS, Dental Impact 5()2, 2013,90-93
- [4]. Ortman HR. The role of occlusion in preservation and prevention in complete denture prosthodontics. J Prosthet De 1971;25:121-38.
- [5]. PyneSH: A posterior set-up to meet individual requirements. Dent Digest 1941;47:20-22.
- [6]. Becker CM , Swoope CC, Guckes AD .Lingualized occlusion for removable prosthodontics. J Prosthet Dent 1977;38:601-608
- [7]. Phoenix R.D.and Engelmeier R.L. Lingualized occlusion revisited . J Prosthet Dent 2010;104:342-346.
- [8]. Winkler S: Essentials of complete denture prosthodontics.ed 2. Philadelphia, PA, WB Saunders 1996.